

Immediate Implantation and Immediate Loading

| Dr. Armin Nedjat

The Champions® implant is not actually considered as a classical “ingrown” implant but rather as an “osteotome implant“ on which a prosthodontic restoration can easily be fitted. Due to the crestal micro-thread of this implant, the lateral surrounding bone can be condensed so that excellent primary stability can be achieved (Fig. 1a-c). This has been proven by long-term studies for several years about bones and aesthetics, such as about aesthetic problems with single front teeth in the upper jaw and immediate implantation. One -piece implants are more beneficial than two-piece implants since due to their design, there is not the problem that the internal screw can loosen or break as is the case with two-piece implants. In addition, there is a lower risk of developing peri-implantitis because of bacteria penetration in the micro-gap, a problem with two-piece implants. In addition, one-piece implants allow a subcrestal implant positioning.

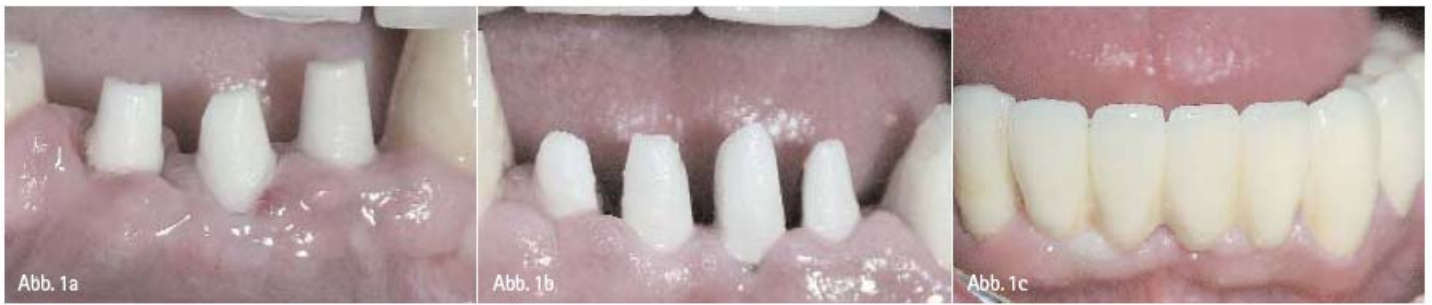

Fig. 1a-c: View of two cases with immediate implantations (extraction and implantation in just one session) with Champions® implants
View of three and four cementable zirconium Prep-Caps, respectively, 14 days after surgery (Fig. 1a–1c: Intraoral camera pictures).

You don't need many instruments (usually, a maximum of two drills) **for the implantation with the Champions® system**. The implantation is quick and virtually “bloodless” for the patient. The patient practically feels no pain, and there are not many complications. In addition, the treatment with the prosthodontic restorations and components for compensating divergences is cost-efficient, and the definitive prosthodontic restoration can usually be fitted within two weeks. Patients appreciate this quick, efficient and practically painless surgery and also that the excellent cost-efficient prosthodontic restoration will be fitted on the implants in such a short time. According to the Champions®-diagram, 90% of the patients are immediately treated with definitive prosthodontic restorations within the first 14 days post surgery, and **for 10% of them, the prosthodontic phase begins** eight weeks after surgery.

In particular for individual single-rooted front teeth **implants** in the upper jaw, this time period of eight weeks after implantation can be necessary before the prosthodontic phase can begin; when **they** are immediately loaded, lateral shear forces (exerted by the lower front teeth and the lower molar and premolar teeth) can lead to losses of individual single upper teeth implants in the upper jaw.

When there are several teeth/implants – definitive prosthodontic restorations can be fitted temporarily, which can be “relined” with ceramics after eight weeks, if necessary. With this procedure there are less complications and problems with the temporary. I have used several cements and cement combinations. It's been for quite a while since I have used Implantlink of Detax, Ettlingen.

The gingiva is not irritated through cement remains, and the superstructure is gentle, protects the nerves, and can be removed after a few weeks or months without any problems, while the gingiva still looks healthy.

As dentists, we need to meet the following demands of the patients for the treatment in current implantology and prosthodontics: a short treatment, the minimally invasive implantation, gentle surgery, first-class aesthetics, and last but not least an affordable whole treatment. We have shown all this in the following case, for which the fitting of the restoration just took 14 days (Fig. 2 to 6).

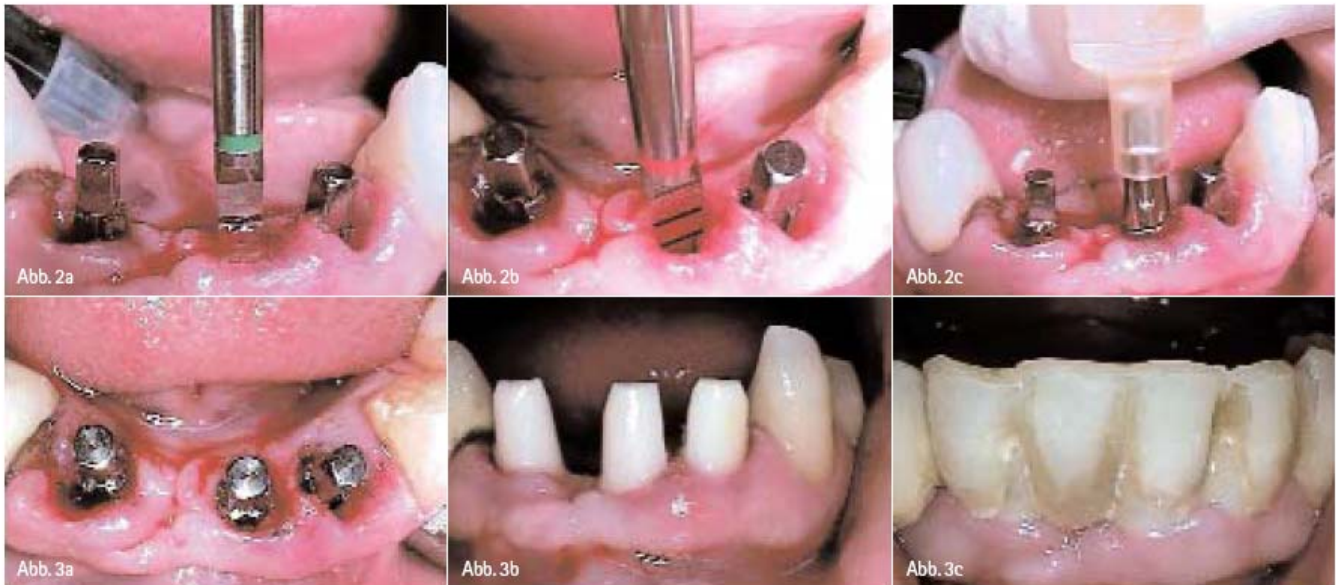


Fig. 2a-c: The teeth 32-42, which could not be maintained in the periodontium, were gently extracted. Then, after a thorough curettage, we drilled in the lingual alveolar wall with two drills: the green Champions triangular drill and the red one, respectively. Then, after the bone cavity had been successfully checked with a sterile periodontal probe, the Champions implants with a diameter of 3,5 mm and with lengths of 16 mm and 14 mm were inserted 2 mm subcrestally.

Fig. 3a-c: After having fitted the Prep-Caps, we cemented them with the Fuji- Glasionomer base cement, 2 mm subgingivally. The purposely short plastic temporary, which did not irritate the mucosa, was fitted with Implantlink. It was taken out twice within 14 days: for fitting the framework and for taking the second bite registration and also for fitting the temporary, semi-permanent supraconstruction with Implantlink. During the 14 days post surgery, the patient rinsed her mouth with a 0.2 % CHX solution. In the first five days post surgery, she took Amoxicillin 1000 mg and Perenterol 250 mg forte twice a day (Fig. 2a-3c: Intraoral camera pictures).

According to our current clinical and X-ray results, it has been shown in recent years that the healing process of the extraction wounds and the ingrowth of the implants (which have the same diameter as the bone cavity) do not have to last several months. On the contrary, this long treatment process has even proven rather disadvantageous.

The dream to have an immediate implantation with immediate loading has come true, which is now also affordable, safe, reliable and also aesthetic for our patients on a long-term basis.

Author.

Dr. Armin Nedjat
Dentist, Implantology Specialist,
Diplomate ICOI
E-Mail: nedjat@t-online.de

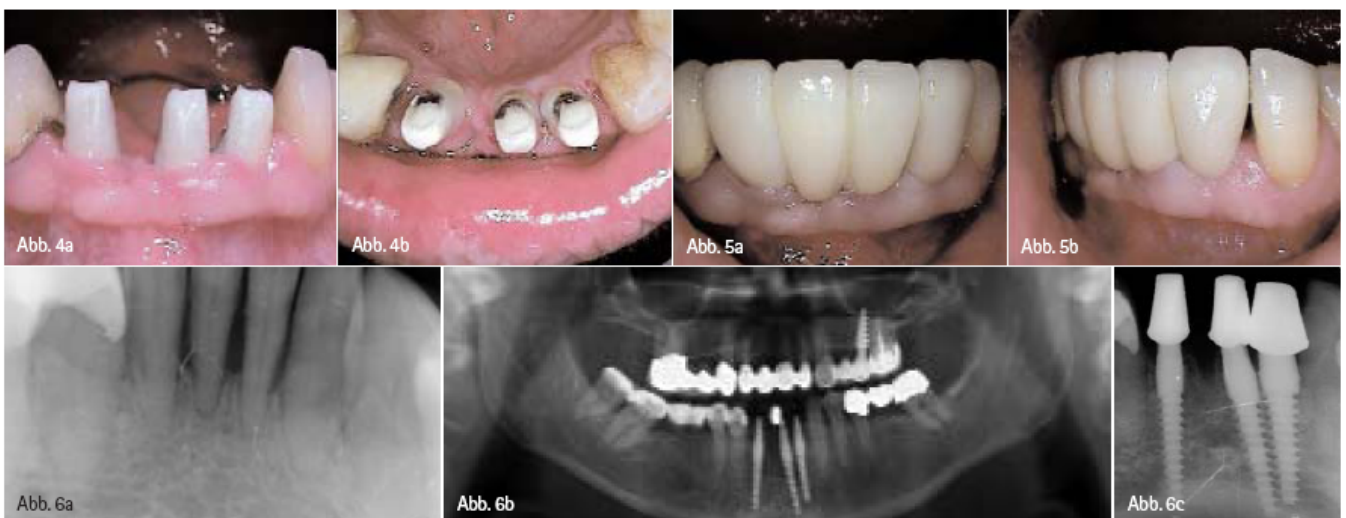

Fig. 4a-b: View of the mucosa, which is not irritated, twelve days post extractionem and implantationem. The remains of the Implantlink cement can be removed completely and without any problems.

Fig. 5a-b: In case the ceramic restoration needs to be "relined" six to eight weeks post surgery, it just takes one to three days until the definitive prosthodontic restoration can be fitted with Implantlink or definitive cement. During the critical phase, the implants are connected two to eight weeks post surgery to allow stability. Over 12 years, long-term studies have shown a success rate of 95 % for this treatment and that periimplantitis does not develop, that there are no prosthodontic complications, such as the loosening and breaking of screws, and that there is no long treatment time (Fig. 4a-5b: Intraoral camera images).

Fig. 6a-b: X-ray pictures: since no non-resorbable bovine oder alloplastic material is used to fill the remaining alveoli, natural bone can completely regenerate. Prep-Caps, in particular those made of zirconium, ensure quick and good GTR (Guided Tissue Regeneration) of the soft tissue and GBR (Guided Bone Regeneration), because the material is bio-friendly. If an immediate implantation has been carried out, the zirconium Prep-Caps function like a permanent membrane that ensures bone growth by preventing the downgrowth of the gingiva.