MIMI®-Flapless Implantation with Single-Tooth Champions Implant (R)Evolution® in the Esthetic Zone

Author: Dr. Stephanie Ott, Dental Care Solutions, Frankfurt/Main

*Please note: The tooth numbers mentioned refer to the FDI Notation System (Dental Chart/Two-Digit World Dental Federation Notation)

As a dentist in private practice, I have placed and restored different implant systems since 2001. For some time, I have incorporated MIMI®-Flapless, the Minimally Invasive Implantation Method, as an additional treatment in my dental office. I am delighted to say that this implantation procedure that is performed without surgical flaps and opened mucosa proves to be less traumatic for patients than the conventional methods of implantation that require reflected flaps and direct visualization of the bone. Most patients feel almost no pain, swelling or post-operative soreness after the surgery. In most cases, patients can resume their activities that day or the next. In this article I would like to describe a case of an implantation of Teeth 11 (#8) and 21 (#9) and the following 8 weeks.

Fig. 1-3: X-rays after the patients' accident that caused a fracture of the zygomatic bone and the nasal septum: view of the roots of Teeth 11 and 21. Both teeth were lost. The clinical situation 4 months post extraction.

Implantation

After administering local anesthesia with UDS-forte, we inserted a Champions® conical triangular yellow drill transgingivally until it was in contact with the periosteum to determine the gingival height and thickness (laser markings: every 2 mm). We measured 2 mm-gingival thickness. We drilled transgingivally and slightly palatinally at a slow rotation speed of a maximum of 250 rpm (no water used) (Fig.4 and 5). After measuring the initial gingival thickness and before placing a 10 mm-Champions Implant (R)Evolution®, we prepared the bone with the following 3 conical triangular drills in the D2/D3 bone: first the yellow drill, followed by the black drill and finally the white drill. These drill types allow the spongy bone to be laterally condensed. Between each drill sequence a bone cavity check is performed. (Bone Cavity Check "BCC" is a manual check of the bone cavity to confirm all walls of the prepped bone are intact.")

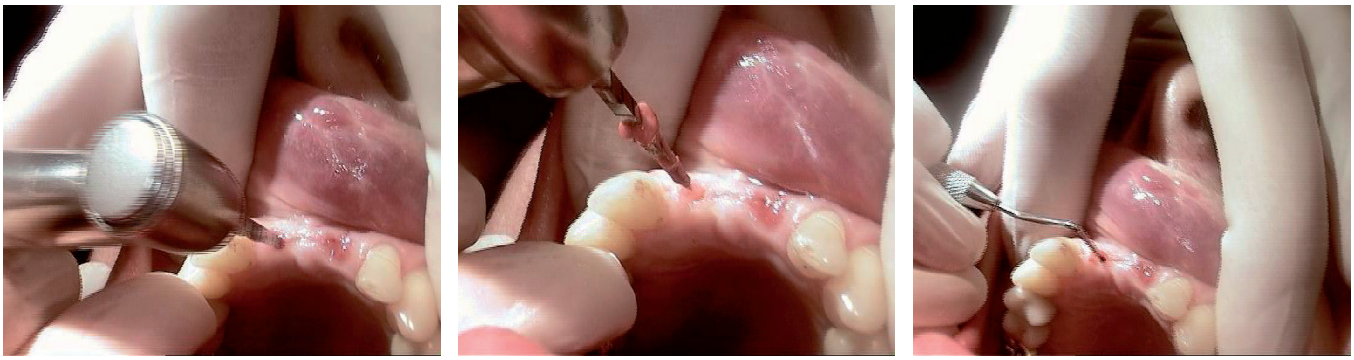

Fig. 4-6: Use of the conical triangular yellow drill to prepare the implantation site using the MIMI®-Flapless technique and Bone Cavity Check (BCC) with the flexible thin BCC probe.

After the drilling, a 3.0 mm-diameter condenser (Fig.9) was used to extend, expand and condense the spongy bone area to confirm the implant size picked was correct. If primary stability cannot be reached, a larger diameter can be placed. In this case, primary stability of 30/40 Ncm was achieved, which was indicated when the Torque Wrench middle line moved from 20 to 40 Ncm and when the arm of the Torque Wrench bent at 40 Ncm (Fig. 10). We unpacked the blister package and removed the sterile Champions (R)Evolution® implant from the vial. As a rule, you can insert the implant manually with the integrated white plastic Insertion Aid that is attached when the package is opened. There is no need to touch the sterile implant or reset the Insertion Aid. Once the resistance becomes so great that you cannot insert any further, you can remove the Insertion Aid and place the gold hex headed metal driver on the implant head. You have 2 choices to continue the insertions: either use a surgical unit with handpiece at very low RPM (5-10 rpm) or use the Torque Wrench on the gold driver. This treatment is non-traumatic and takes only a few minutes. In this case, the Torque Wrench was used to drive the implants on both 11 (#8) and 21 (#9) to the desired depth. The total time for both placements was less than 1 hour. Finally, X-rays were taken. The patient was very satisfied. She compared this to a friend who had conventional implantation in another office that took two hours to complete.

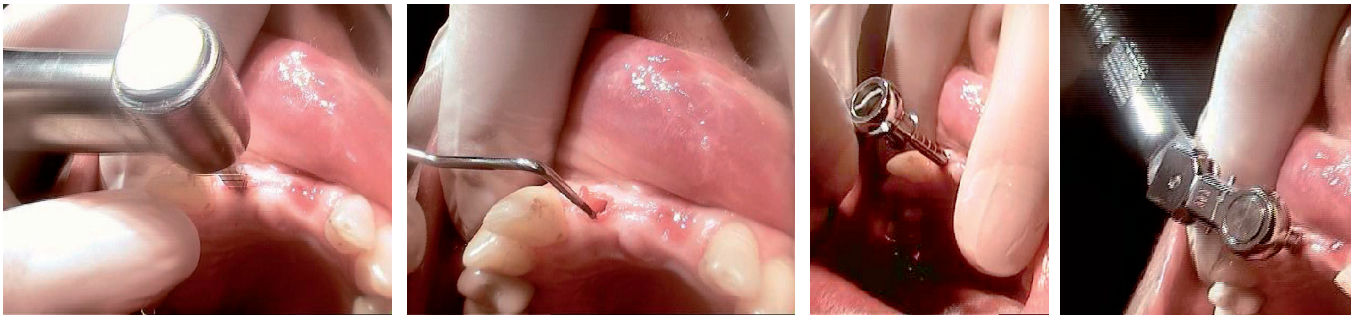

Fig. 7 - 10: After drilling with the yellow, black, and white conical triangular drills in the soft D3/D4 bone, condensers were used with the Torque Wrench. The Torque Wrench was adjusted to 20 Ncm. When the scale sleeve bent around the axis of the Torque Wrench at 40 Ncm and the middle line moved from 20 to 40 Ncm, primary stability at 40 Ncm was reached.

Fig.11 - 13: Manual insertion of Champions Implant (R)Evolution® Shuttles by means of the Insertion Aids. The Shuttle (also playing the role of transgingival healing) should not stick out of the tissue more than 1 mm to avoid strong lateral shear forces of occlusion particularly during the first 2-6 weeks post surgery.

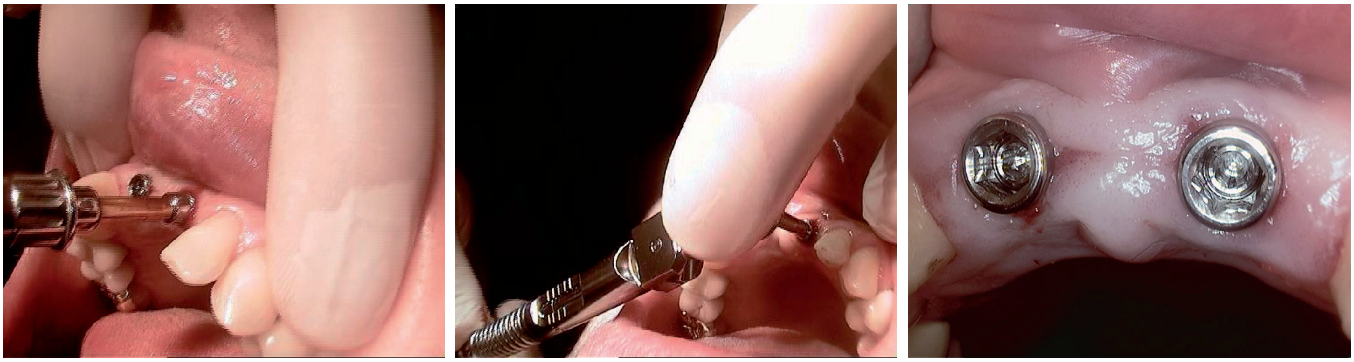

Fig. 14 - 16: The second implant, including the bacteria-proof Shuttle, was placed. The 3.5 mm-high Shuttle is fastened with 10 Ncm from the factory. The implant and Shuttle were placed so only 1 mm of the Shuttle was supragingival. As a rule, if the mucosa is less than 3 mm thick before drilling, subcrestal drilling and positioning of the implant will be preferable to prevent the Shuttle from sticking out more than 1 mm above the gingival height, thus preventing lateral shear forces and movement on the Shuttle head.

Fig. 17 - 19: After taking X-rays, a WIN! Gingiva-Clix was set on the Shuttle of each Champions Implant (R)Evolution®. Then, a temporary prosthetic restoration (Maryland bridge) was fitted and cemented with Fynal (Dentsply).

Impression & Laboratory & Prosthetic Restoration

During the seven weeks post surgery (Transition between Primary Osseointegration Stability and Secondary Osseointegration Stability), the patient felt no pain and experienced no complications. Seven weeks post surgery, the temporary restoration and Gingiva-Clix were removed. A closed transgingival Impregum impression of the implants was made through the Shuttles. The Gingiva-Clix were replaced on the Shuttle and the temporary restoration recemented. The supragingival treatment lasted 15 minutes without the need of anesthesia or X-rays. Our German laboratory, DENTworry in Alzenau, Germany, manufactured two individual zirconium-coated crowns. It is important to provide the laboratory with both Implant Analogs and Shuttles to preserve the exact location of the implant and the soft tissue contour. The lab should use gingival mask material to simulate soft tissues.

After a week, the Shuttles, including the screws, were removed for the first time. The angled titanium Abutments were placed using a resin key and screwed in to a torque of 30 Ncm. The final crowns (zircon) were fitted and cemented.

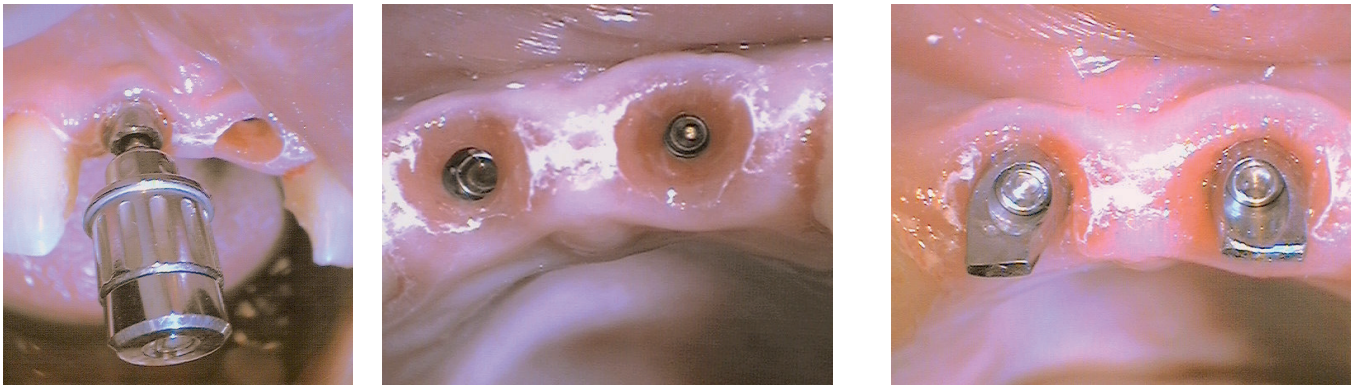

Fig. 20 - 22: After unscrewing the retaining screw from the Shuttle/Implant, the Shuttle Extractor (R)Evolution was used to remove the Shuttle. With the adapter, the Shuttle Extractor was manually screwed clockwise in through the Shuttle and into the implant. This lifts the Shuttle off of the implant. Favorable peri-implant soft-tissue results are observed from the Shuttle and Gingiva-Clix. Before the removal of the Shuttle and placement of the Abutments, the inner diameter of the implant has remained sterile during 6-8 week healing. This prevents the problems of peri-implantitis around the healing implant. The titanium Abutments are screwed in and torqued to 30 Ncm, and the screw shafts are covered with cotton pellets and Cavit.

The implant/Abutment can be connected with the same screw as the one removed from the Shuttle that was connected to the implant. In this case, the crowns were fitted and cemented in only 15 minutes without anesthesia. Highly esthetic results were obtained.

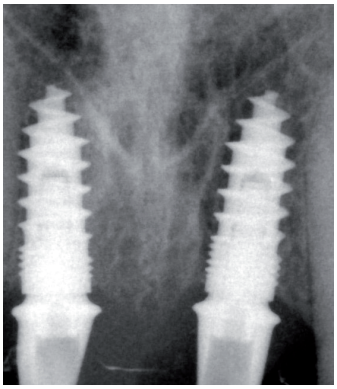

Fig. 23: X-rays.

Fig. 24 and 25: After fitting the Abutments and the crowns, excellent esthetic results in the buccal and palatinal areas were obtained.

Conclusion

Apart from the advantages of the non-traumatic, efficient and time-saving treatment, the innovative and high-quality Champions Implant (R)Evolution® and prosthodontic restorations are more affordable for patients than conventional implantation (total price: 135 €, including Gingiva-Clix, angled Abutment, Laboratory Analog, Shuttle, and impression, laboratory and dental accessories). This implant system has now been fully integrated into the treatment services offered in my dental office. I don't want to be without it!! The innovative Champions Implant (R)Evolution® is a real "Revolution".

In fact, the MIMI®-Flapless method is very promising for patients. Over the past 10 years, international scientific studies at universities have shown that the MIMI®-Flapless method is very beneficial. One of the many advantages of the system is no need of re-entry in the gingival tissue during the impression or when the final restorations are placed. Many patients are enthusiastic about MIMI®-Flapless implantation techniques and the Champions® implants.

Please watch the video of this case here:

https://vimeo.com/75207980

Author: Dr. Stephanie Ott

DENTAL CARE SOLUTIONS

Leipziger Strasse 4 · 60487 Frankfurt am Main

Tel. + 49 (0) 69 - 97 78 33 66

Internet: www.dr-ott.net

Mail: rezeption@dr-ott.net