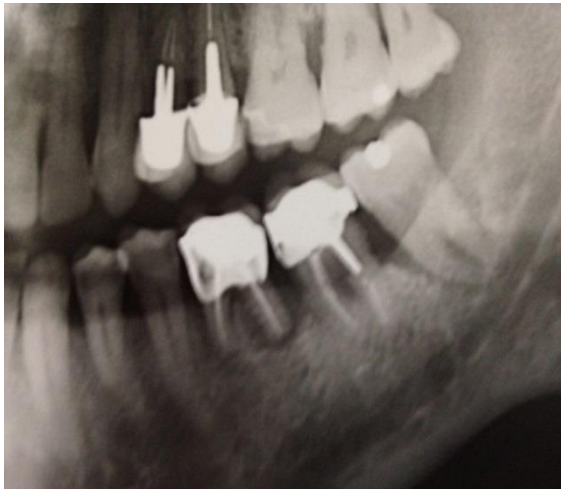

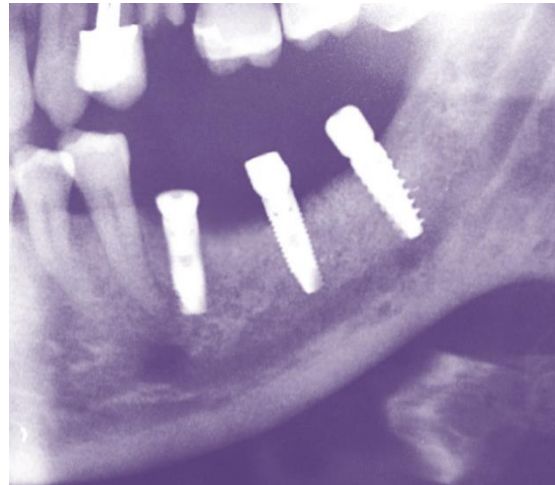Advanced periodontal disease

Case description: same patient M56, left side of mandible. Here three teeth were extracted #36,37 and 38. Only one tooth was ground and grafted immediately into defect.


Results: After two month implant stability is achieved. Prosthetic device was accomplished following healing of implant procedure. **A one year follow up shows that autologous tooth graft is best for long lasting implant stability.**



Prior to treatment



2 month after grafting implant insertion.



One year follow up